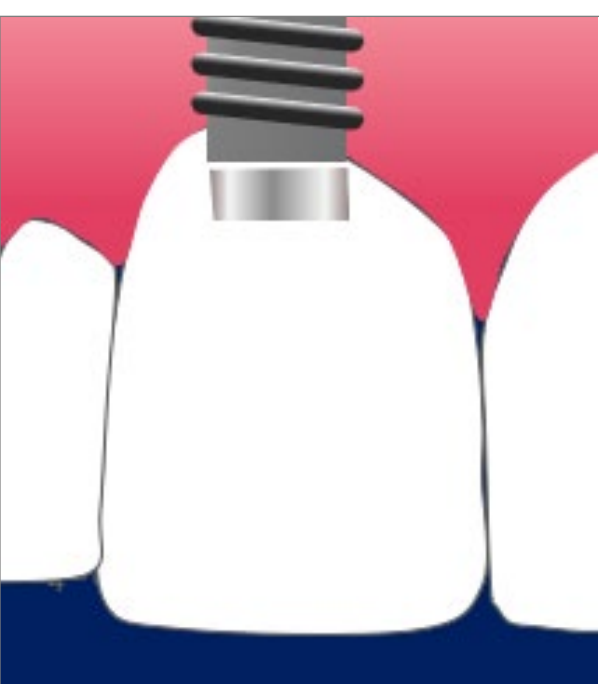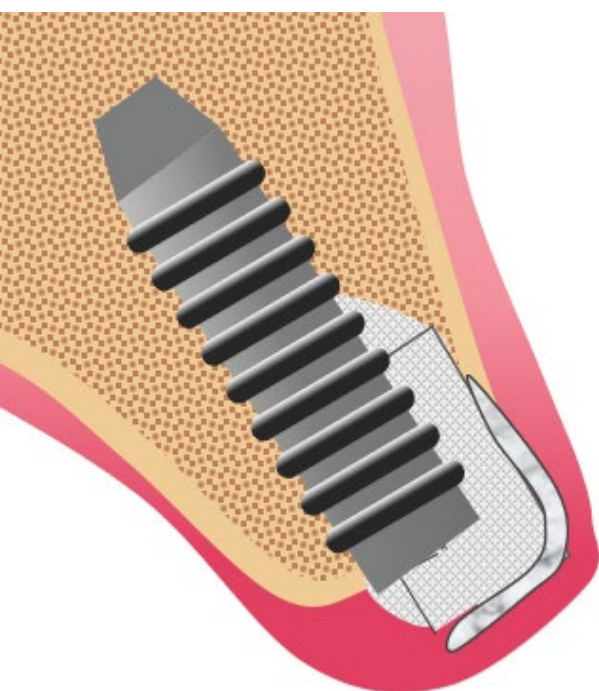


Minor Bone Augmentation

L-Shape Technique: Very good and stable results after up to 14 years



Following *mean values* were obtained:

Pink esthetic score (0-14):	10.7	
White esthetic score (0-10)	8.8	
Patient satisfaction (0-10)	9.5	
Marginal bone level (mm)	0.7	
Keratinized tissue width (mm)	2.9	
Probing depth (mm)	2.7	

Key Message

The L-shape augmentation procedure seems to be a reliable technique when performing GBR with simultaneous implant placement in the esthetic zone: stable clinical & esthetic results, high patient satisfaction.

Study results

- Volumetric analyses revealed minimal changes at the augmented sites irrespective of the region of interest
- Radiographic marginal bone level remained relatively stable
- Stable clinical and favorable esthetic outcomes
- High levels of patient satisfaction



Retrospective study



14



2.6-14.3 years
(7.7 ± 3.8 years)



Evaluate clinical benefits of L-Shape bone augmentation simultaneous with implant placement in the aesthetic area

