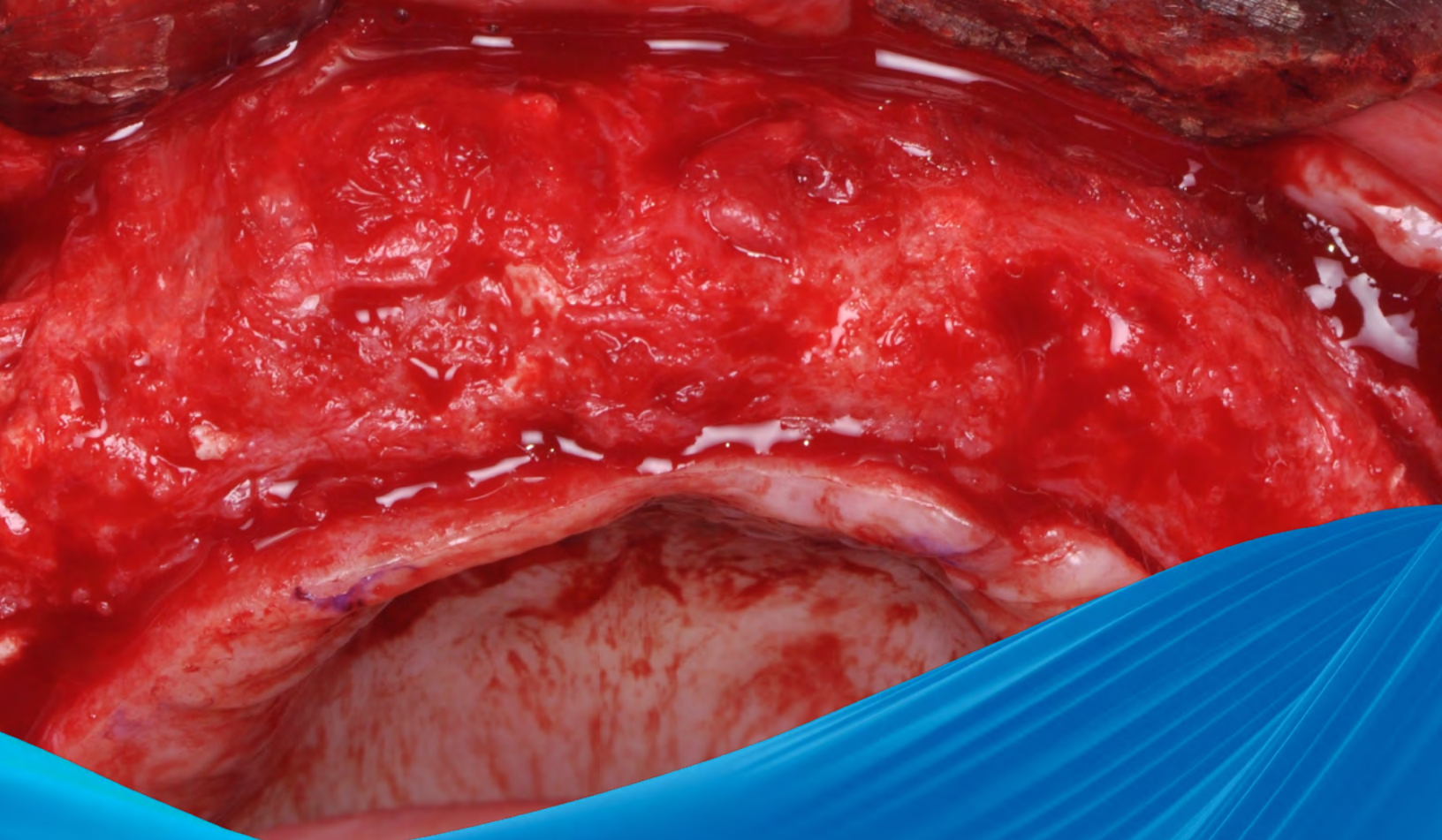

# BioBrief

MAXILLARY RIDGE RECONSTRUCTION

Nikolaos Soldatos, DDS, PhD, MSD

## Vertical and Horizontal Maxillary Ridge Reconstruction with Advanced Grafting

leading regeneration

Geistlich

Curious  
about other  
BioBriefs?



# The Situation

A 26-year-old edentulous female presented for implant-supported maxillary rehabilitation. She was systemically healthy and classified as ASA I. Clinical and radiographic evaluation revealed a Seibert Class III maxillary ridge defect with combined horizontal and vertical deficiencies. The patient exhibited a medium smile line and reported a highly active lifestyle with regular physical activity, indicating the need for a stable, durable, and esthetically driven implant rehabilitation capable of meeting long-term functional demands.

# The Approach

Horizontal and vertical ridge augmentation was performed using a full-thickness maxillary flap with two distal vertical releasing incisions. Extensive buccal periosteal release and cortical perforations were carried out. A composite graft of large-particle vallos<sup>®</sup> allograft (demineralized cortical granules) and large-particle Geistlich Bio-Oss<sup>®</sup> xenograft, combined with rhPDGF-BB, a component of GEM 21S<sup>®</sup>, was placed and stabilized under a high-density PTFE membrane, which was secured with four horizontal mattress and multiple simple interrupted 4-0 PTFE sutures.

# The Risk Profile

	Low Risk	Medium Risk	High Risk
Patient's Health	Intact immune system (non-smoker)	Light smoker	Impaired immune system
Patient's esthetic requirements	Low	Medium	High
Height of smile line	Low	Medium	High
Gingival biotype	Thick - "low scalloped"	Medium - "medium scalloped"	Thin - "high scalloped"
Infection at implant sight	None	Chronic	Acute
Soft-tissue anatomy	Intact		Compromised
Bone anatomy of the alveolar ridge	No defect	Horizontal defect	Vertical defect

## Nikolaos Soldatos, BDS, PhD, MSD | Portland, Oregon

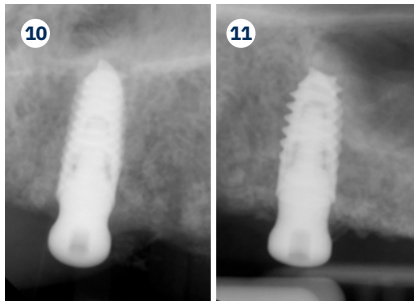
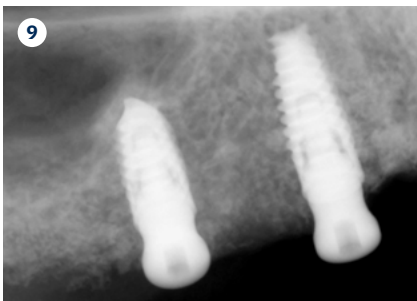
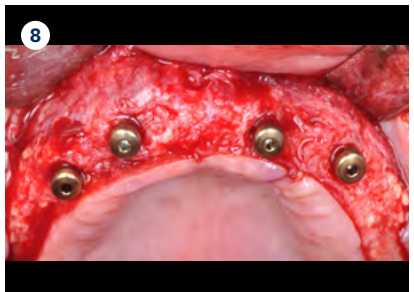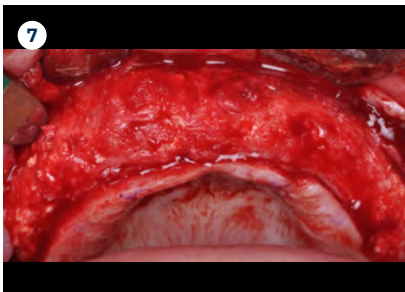
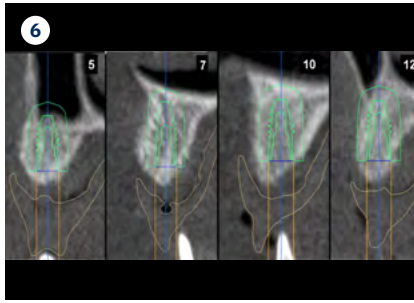
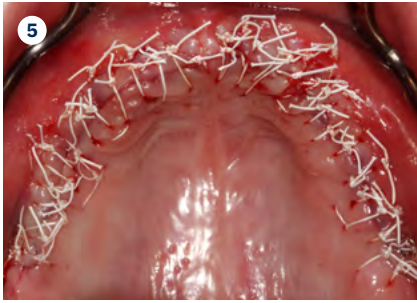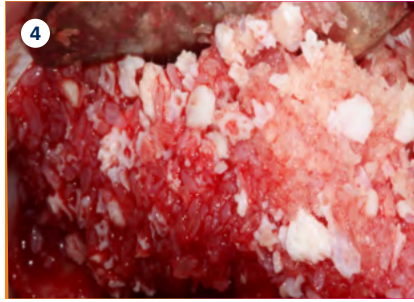
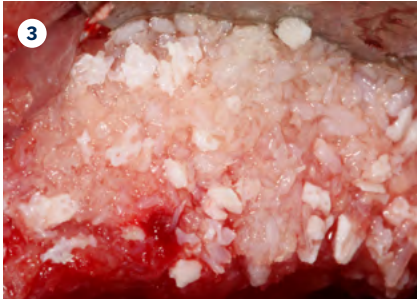
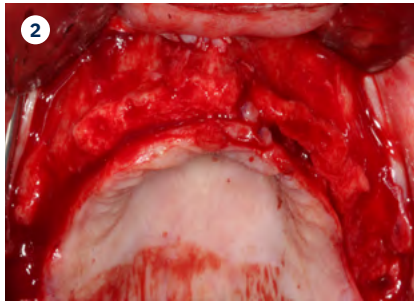
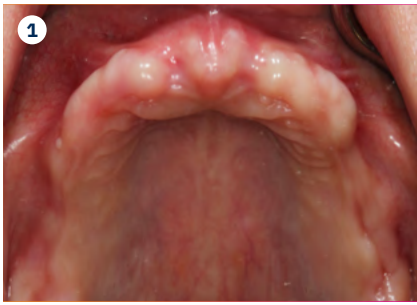Periodontist

 Nikolaos K. Soldatos

Dr. Soldatos is a tenure-track Associate Professor and Clinical Director of the Postgraduate Advanced Program in Periodontics at Oregon Health & Science University. He is a Board-Certified Periodontist and Implant Surgeon, he holds a DDS, PhD, and MSD, and has completed advanced periodontal and implant training in both the U.S. and Europe. Dr. Soldatos' research focuses on translational implant biology and bone regeneration. He is also a Fellow of the Academy of Osseointegration.



“ The patient’s young age and excellent systemic health are favorable prognostic factors, but achieving optimal outcomes requires meticulous surgical execution, careful soft tissue management, and strict adherence to postoperative instructions to minimize complications and ensure long-term success.”



## The Outcome

Horizontal (5–7 mm) and vertical (3–4 mm) ridge augmentation were successfully obtained, with stablewound management achieved through precise suturing techniques. The osteoinductive properties of the large vallos<sup>®</sup>, demineralized granules combined with rhPDGF-BB, a component of GEM21S<sup>®</sup> promoted high-quality bone regeneration, whereas the large Geistlich Bio-Oss<sup>®</sup>, xenograft particles contributed to volume preservation by moderating resorption. As a result, four 4.3 mm implants were placed with high primary stability, each exceeding 35 N-cm of insertion torque, providing a strong foundation for a predictable esthetic and functional restoration.

- 1 Pre-operative occlusal photograph of the maxillary arch showing a pronounced Seibert Class III ridge deformity, with simultaneous horizontal and vertical soft and hard tissue loss in the edentulous area.
- 2 Intraoperative view following reflection of full-thickness flaps, revealing a pronounced combined horizontal and vertical ridge deficiency.
- 3 Upper left view showing the mixture of large-particle vallos<sup>®</sup> allograft, demineralized cortical granules, and large-particle Geistlich Bio-Oss<sup>®</sup> xenograft, combined with rhPDGF-BB, a component of GEM 21S<sup>®</sup>.
- 4 Upper right view showing the mixture of large-particle vallos<sup>®</sup> allograft, demineralized cortical granules, and large-particle Geistlich Bio-Oss<sup>®</sup> xenograft, combined with rhPDGF-BB, a component of GEM21S<sup>®</sup>.
- 5 Closure of the maxilla was achieved using a PTFE-barrier membrane and 4-0 PTFE sutures. Horizontal mattress sutures were placed to provide initial tension relief and flap stabilization, while simple interrupted sutures were used for precise approximation of the wound margins.
- 6 Six-month postoperative CBCT images with virtual implant planning reveal sites #5, 7, 10, and 12, exhibiting 5–7 mm of horizontal ridge augmentation and 3–4 mm of vertical ridge augmentation.
- 7 Intraoperative view demonstrating vertical and horizontal ridge augmentation at 7 months following the initial augmentation procedure.
- 8 Intraoperative view of four tapered, internal-connection implants placed at 35 N-cm with standard-platform healing abutments torqued to 15 N-cm.
- 9 A 4.3 × 8 mm tapered implant with crestal sinus elevation was placed at site #5, and a 4.3 × 10 mm tapered implant was placed at site #7.
- 10 A 4.3 × 10 mm implant was inserted at the site.
- 11 Placement of a 4.3 × 10 mm implant in conjunction with a crestal sinus elevation.

Geistlich Pharma North America, Inc.  
 Princeton, NJ 08540  
 Customer Care Toll-free:  
 855-799-5500  
 info@geistlich.com  
 www.geistlich.us

## Keys to Success



- Proper flap design incorporating vertical releasing incisions
- Proper flap management with buccal periosteal release
- Cortical perforations
- A graft mixture composed of vallos<sup>®</sup>, a large-particle osteoinductive allograft, Geistlich Bio-Oss<sup>®</sup>, a large-particle xenograft, and rhPDGF a platelet-derived growth factor which is a component of GEM 21S<sup>®</sup>
- Tension-free primary closure and excellent wound stability obtained through meticulous suturing, utilizing four horizontal mattress sutures and multiple interrupted 4-0 PTFE sutures
- Patient adherence to the strict postoperative instructions



## My Instruments

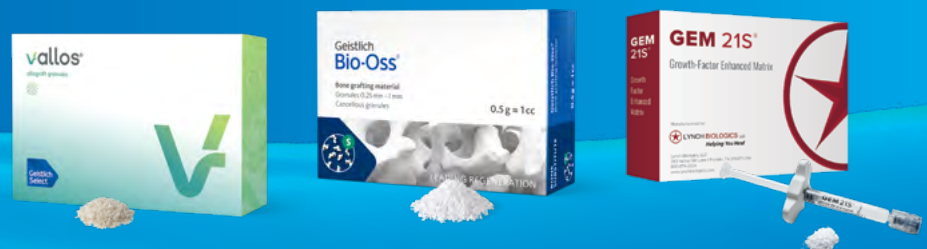- Large vallos<sup>®</sup> demineralized cortical granules (850-2000 µm)
- Large Geistlich Bio-Oss<sup>®</sup> granules (1-2mm)
- rhPDGF, a component of GEM 21S<sup>®</sup>
- PTFE sutures

For more information, please visit:  
[www.geistlich.us](http://www.geistlich.us)

CAUTION: Federal law restricts these devices to sale by or on the order of a dentist or physician.

For more information on contraindications, precautions, and directions for use, please refer to the Instructions for Use at:  
<https://www.geistlich-na.com/dental-professionals/instructions-for-use>

Disclaimer: These results are not guaranteed; individual outcomes may vary depending on patient circumstances. This information is for informational purposes only and may not reflect Geistlich's official position, opinion, or recommendation. Treatment decisions are made at the physician's discretion, based on the unique needs of each patient.



“

The combination of rhPDGF-BB, a component of GEM 21S<sup>®</sup>, promotes enhanced bone regeneration by stimulating cellular proliferation and osteogenesis. When supplemented with Geistlich Bio-Oss<sup>®</sup>, which maintains graft volume through slow resorption kinetics, this approach provides predictable ridge augmentation. Together, these graft components support stable, high-quality bone formation and foster optimal conditions for long-term implant integration.”