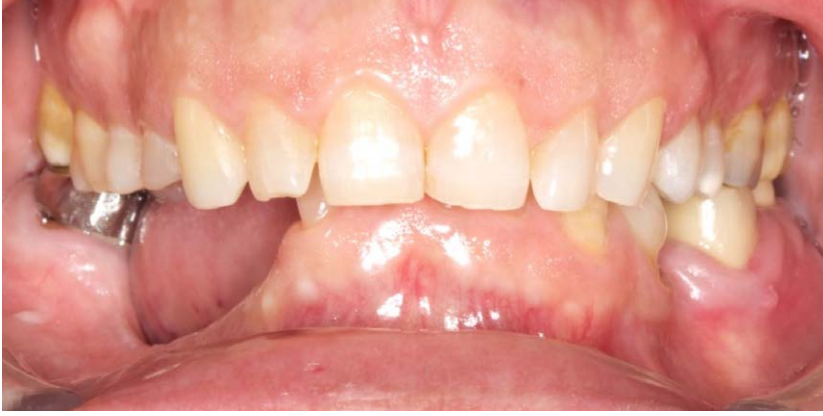



A CASE REPORT BY
Dr. Gian Maria Ragucci
Prof. Federico Hernández-Alfaro

**Combined Horizontal and
Vertical Regeneration
using a CAD-CAM
Titanium Scaffold**



► The Situation

A 54-year old, systematically healthy male patient (*ASA) came to our attention presenting with partial edentulism in the lower jaw and requiring a fixed and esthetic rehabilitation, refusing any removable solution. The clinical and radiographic evaluation resulted in significant bone atrophy both in the vertical and horizontal components; which makes it impossible to place both conventional implants and short or narrow implants.

► The Risk Profile

Esthetic Risk Factors	Low Risk	Medium Risk	High Risk
Patient's health	Intact immune system	Light smoker	Impaired immune system
Patient's esthetic requirements	Low	Medium	High
Height of smile line	Low	Medium	High
Gingival biotype	Thick - "low scalloped"	Medium - "medium scalloped"	Thin - "high scalloped"
Shape of dental crowns	Rectangular		Triangular
Infection at implant site	None	Chronic	Acute
Bone height at adjacent tooth site	≤ 5 mm from contact point	5.5 - 6.5 mm from contact point	≥ 7 mm from contact point
Restorative status of adjacent tooth	Intact		Restored
Width of tooth gap	1 tooth (≥ 7 mm)	1 tooth (≤ 7 mm)	2 teeth or more
Soft tissue anatomy	Intact		Compromised
Bone anatomy of the alveolar ridge	No defect	Horizontal defect	Vertical defect

*American Society of Anesthesiologists Physical Status Classification System

SPECIAL INTEREST

Guided Bone Regeneration

"The use of CAD-CAM Titanium scaffold Yxoss CBR® allows an ideal bone regeneration and a faster and easier surgery."

– Dr. Gian Maria Ragucci

Gian Maria Ragucci, DDS, MSc

Universitat Internacional de Catalunya (UIC), Barcelona
Dental degree at Universidad Europea de Madrid 2015
International Master in oral surgery at UIC, Barcelona 2018
PhD student at UIC, Barcelona 2018
EAO Certification program in implant dentistry 2018
EAO European prize in implant dentistry 2019

Federico Hernández-Alfaro, MD, DDS, PhD, FEBOMS

Full professor & Chairman, Department of Oral and Maxillofacial Surgery, UIC, Barcelona
Institute of Maxillofacial Surgery, Teknon Medical Center, Barcelona



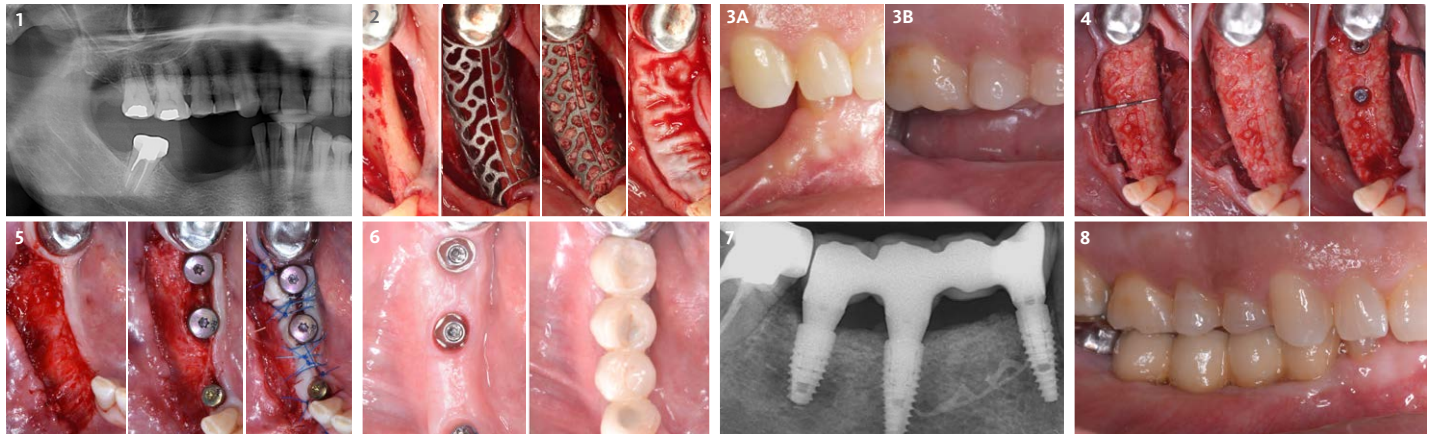
Dr. Gian Maria Ragucci



Prof. Federico Hernández-Alfaro

► The Approach

Solving the case was developed in two steps: first bone reconstruction to restore the ideal anatomy, second positioning of the prosthetically guided implants. An individualized regeneration technique was chosen using a CAD-CAM titanium scaffold (Yxoss CBR®) in conjunction with a mix of 60% autogenous bone and 40% Geistlich Bio-Oss®, covered by Geistlich Bio-Gide®. At 9 months, the titanium scaffold was easily removed and 3 prosthetically guided implants were placed, completely surrounded by bone. At 12 months, a free gingival graft was performed to re-establish the missing amount of keratinized mucosa. Finally, at 16 months, the final rehabilitation was carried out with a fixed prosthesis on implants.



1 Panoramic radiographic view of the defect.

2 Horizontal and vertical augmentation step by step.

3 (A) Baseline situation.
(B) 9-month follow-up.

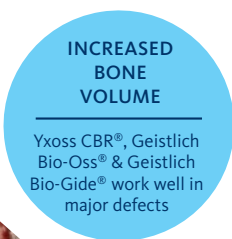
4 Scaffold removal and implant placement step by step.

5 Soft tissue management with free gingival graft.

6 Final restoration.

7 Periapical radiograph of implants and prosthesis.

8 Final restoration at 16 months.



“Combined horizontal and vertical bone augmentation utilizing a CAD CAM titanium scaffold can be achieved with less surgical time and less complications”.

(See image to the left)

► The Outcome

The final resolution of the case was very satisfactory. There were no complications during all the procedures performed. The Yxoss CBR® allowed for easier reconstructive surgery and a significant reduction in surgical times, thanks to the precise dimensions of the scaffold. This resulted in a favorable post-operative situation for the patient and complications were prevented.

Briefly Speaking

► Keys to Success

1. The scaffold was fixed with 2 titanium micro screws
2. Substantially reduced surgery time vs. the utilization of conventional, non-individualized titanium meshes
3. Augmentation performed with a mix of 60 % autogenous bone particles and 40 % Geistlich Bio-Oss®
4. Resorbable collagen membrane, Geistlich Bio-Gide®, in order to optimize the barrier effect



► My Biomaterials

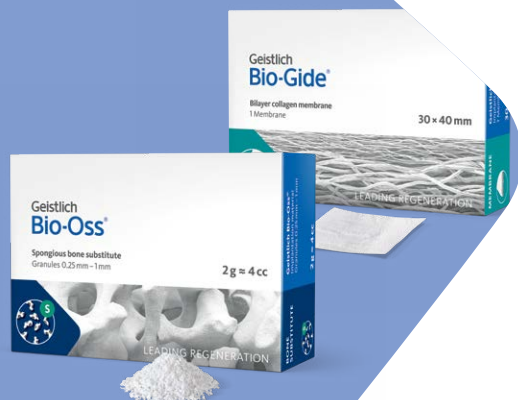Geistlich Bio-Oss® to ensure long-term volume stability, Geistlich Bio-Gide® for barrier function and Yxoss CBR® Customized CAD CAM titanium scaffold for graft containment and stability.

“Vertical bone reconstruction combining the use of Yxoss CBR®, Geistlich Bio-Oss® and Geistlich Bio-Gide® allows a predictable regenerative procedure that is able to create sufficient bone volume suitable for prosthetically guided implant placement.”


– Dr. Gian Maria Ragucci

Geistlich Bio-Gide®
Geistlich Bio-Oss®
Yxoss CBR®

The ideal combination
for major bone
augmentation



Yxoss CBR®
manufactured by
ReOss®



Click here to view the webinar

Geistlich Pharma North America, Inc.

Princeton, NJ 08540

Customer Care Toll-free: 855-799-5500

info@geistlich-na.com

dental.geistlich-na.com

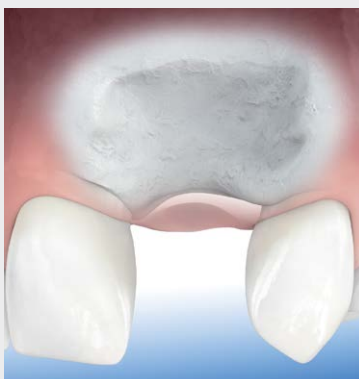ABOUT BIOBRIEF

We know that exposure to new or refined treatment approaches brings innovation to practice. Geistlich Biomaterials is pleased to introduce a periodic opportunity to get up close and personal with creative clinicians from around the world. Focused on peer-to-peer exchange, BIOBRIEF features clinically relevant cases and techniques in specific therapeutic areas – highlighted with valuable insights about materials and instrumentation, as well as KEYS TO SUCCESS.

Geistlich Biomaterials – bringing you *regeneration on time*.

▶ The Therapeutic Area

Geistlich biomaterials can play a significant role in the treatment of major bone defects. Geistlich Bio-Oss® and Geistlich Bio-Gide® are the ideal combination for use with the Yxoss CBR® customized CAD CAM titanium scaffold for regenerating vertical and horizontal bone in major bone augmentation procedures.



CAUTION: Federal law restricts these devices to sale by or on the order of a dentist or physician.

Indications:

Geistlich Bio-Oss® is indicated for the following uses: Augmentation or reconstructive treatment of the alveolar ridge; Filling of periodontal defects; Filling of defects after root resection, apicoectomy, and cystectomy; Filling of extraction sockets to enhance preservation of the alveolar ridge; Elevation of the maxillary sinus floor; Filling of periodontal defects in conjunction with products intended for Guided Tissue Regeneration (GTR) and Guided Bone Regeneration (GBR); and Filling of peri-implant defects in conjunction with products intended for GBR.

Warnings:

Possible complications which may occur with any surgery include swelling at the surgical site, flap sloughing, bleeding, local inflammation, bone loss, infection or pain.

Indications:

Geistlich Bio-Gide® is indicated for the following uses: Augmentation around implants placed in immediate or delayed extraction sockets; localized ridge augmentation for later implantation; alveolar ridge reconstruction for prosthetic treatment; filling of bone defects after root resection; cystectomy and removal of retained teeth and guided bone regeneration in dehiscence defects.

Warnings:

As Geistlich Bio-Gide® is a collagen product, allergic reactions may not be totally excluded. Possible complications which may occur with any surgery include swelling at the surgical site, flap sloughing, bleeding, dehiscence, hematoma, increased sensitivity and pain, bone loss, redness and local inflammation.

For more information on contraindications, precautions, and directions for use, please refer to the Geistlich Bio-Oss® and Geistlich Bio-Gide® Instructions for Use at: www.dental.geistlich-na.com/ifu