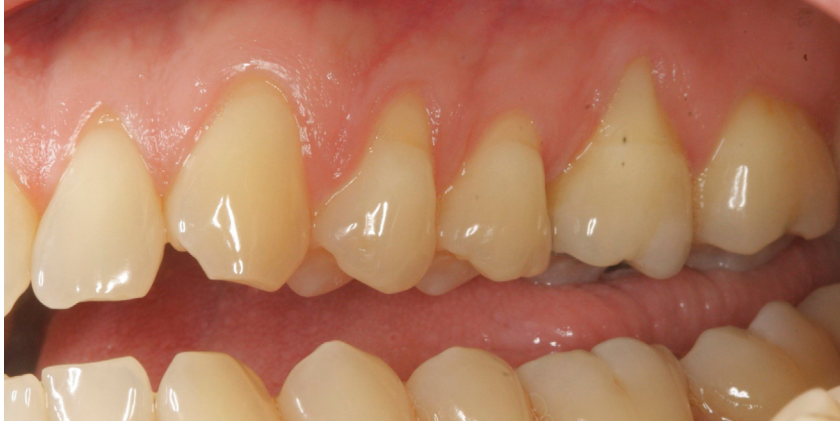



A CASE REPORT BY
DR. DANIEL GOBER

Geistlich Mucograft®
for the treatment of
multiple adjacent
recession defects:
A more “palatable” option

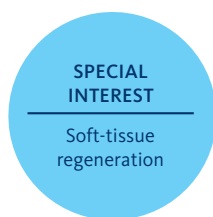


► The Situation

A 35 year old male presented in my practice with a chief complaint of recession. Multiple buccal recession defects ranging 2-5 mm were noted by teeth #11-14 with a minimal amount of keratinized tissue on the buccal of #14. Bone levels were within normal limits with no loss of interproximal tissue observed. These recession defects are classified as Miller Class I recession defects. Typically, 100% root coverage is expected for recession defects of this type.

► The Risk Profile

Esthetic Risk Factors	Low Risk	Medium Risk	High Risk
Patient's health	Intact immune system	Light smoker	Impaired immune system
Patient's esthetic requirements	Low	Medium	High
Height of smile line	Low	Medium	High
Gingival biotype	Thick - "low scalloped"	Medium - "medium scalloped"	Thin - "high scalloped"
Bone defect(s)	Not present	Slight defect <2mm	Significant defect >3mm
Keratinized tissue	Adequate 5mm	Inadequate <5mm	Inadequate <3mm
Miller Classification	Class I - II	Class III	Class IV



“The patient was unhappy with the post-operative morbidity he experienced as a result of the previous connective tissue graft.”

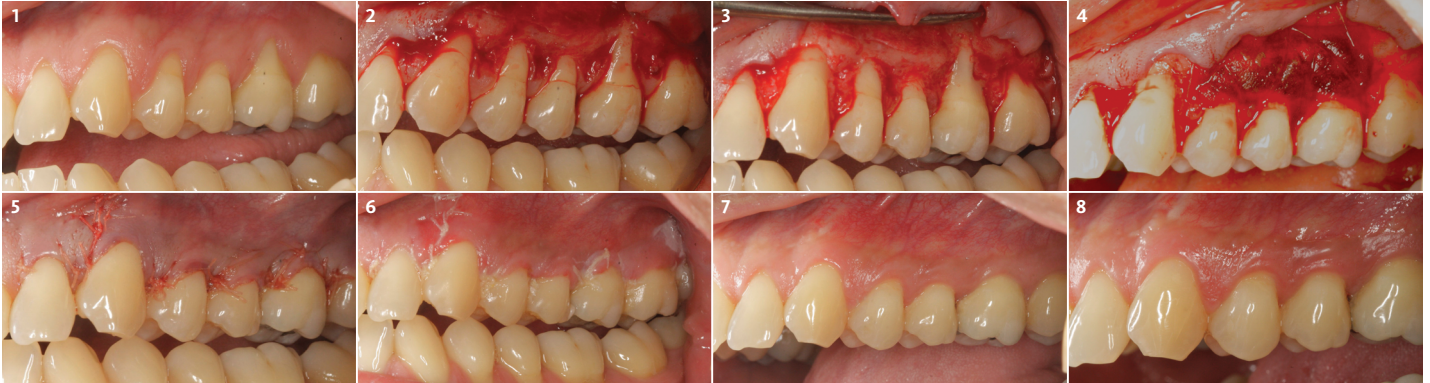DANIEL GOBER, DDS • CEDARHURST, NY
Periodontist - Nova Southeastern University

Dr. Daniel D. Gober received his DDS from SUNY Stony Brook School of Dental Medicine in 2010. He completed his residency in periodontics and implantology at Nova Southeastern University. Dr. Gober is board certified by the American Academy of Periodontology and is a Diplomate of the International Congress of Oral Implantology. He is also certified in the administration of IV sedation and specializes in soft-tissue procedures around both natural teeth and implants. He currently practices in Cedarhurst, NY at South Island Periodontics & Implantology, PLLC.



► The Approach

My Treatment goals included completing root coverage of the recession defects and augmentation of the width of attached keratinized tissue by tooth #14. My patient had similar recession defects on teeth #3-6 which were previously treated with an autogenous sub-epithelial connective tissue graft. Instead of autogenous tissue grafting, Geistlich Mucograft®, a xenogenic collagen matrix, was used in conjunction with a coronally advanced flap.



- 1 Pre-operative view of recession defects. Recession ranges from 2-5 mm. There is minimal keratinized tissue on #14. Pocket depths are within limits with no loss of interproximal tissue.
- 2 A 15c blade is used to make sulcular incisions with scooping incisions at the level of the CEJ. A combination flap consisting of full-thickness coronally followed by a partial-thickness dissection apically is reflected.
- 3 The papillary tissue is de-epithelized with a football diamond bur on a rotary handpiece. This exposes a vascular bed for the graft and intended coronal positioning of the flap.
- 4 Geistlich Mucograft® is trimmed and positioned to extend beyond the root surfaces. A combination of simple interrupted sutures at its coronal edge and mattress sutures extending over the entire graft are used to adapt the graft to the recipient site.
- 5 The flap is then advanced and coronally positioned with horizontal mattress sutures to release tension and simple interrupted sutures to approximate the flap edges to the de-epithelized papillas.
- 6 1 week post-operative visit. Note that the flap margins appear stable. Erythema and edema evident with maturation of the tissue beginning.
- 7 3 months post-operative. Maturation of the tissue evident with complete root coverage evident. An increase in the zone of keratinized tissue by #14 is also visible.
- 8 Stability of the graft is evident at the 1 year post-operative visit. Complete root coverage and a healthy and maintainable gingival complex has been achieved.

Root Prominence

May be a contributing factor for the presence of recession defects

“Geistlich Mucograft® is a viable alternative to an autogenous tissue graft for the treatment of recession defects.”

► The Outcome

This case illustrates the successful use of Geistlich Mucograft®, a xenogenic collagen matrix, for the treatment of multiple adjacent recession defects. Complete root coverage and an increase in the zone of keratinized tissue was obtained and a dento-gingival complex that is amenable to long-term health and stability was achieved. My patient was spared from the inevitable morbidities associated with a sub-epithelial connective tissue graft from a palatal donor site.

Briefly Speaking

► Keys to Success

1. Tedious flap management
 - > Adaptation of the flap to the recipient bed
 - > Tension-free coronal positioning of the flap
2. Passive adaptation of the graft matrix
3. Complete graft coverage

► My Instruments

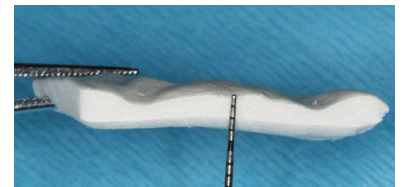
- A. 15c blade (Paragon)
- B. Buser periosteal elevator (Hu-Friedy)
- C. 1920 Football Diamond Bur (Meisinger)
- D. 36/37 Rhodes Back-Action Periodontal Chisel (Hu-Friedy)
- E. Geistlich Mucograft® (Geistlich Biomaterials)
- F. 6-0 Vicryl (Ethicon)
- G. 5-0 Chromic Gut (Ethicon)
- H. Castroviejo needle holder (Hu-Friedy)

► My Biomaterial

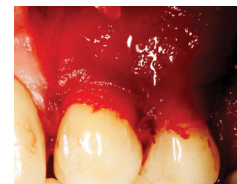- Geistlich Mucograft® requires no pre-treatment or hydration prior to application. The matrix is applied to the defect dry and will moisten rapidly due to its hydrophilic properties. The flap should be sutured tension-free to avoid compression.



“Due to its ability to smoothly and meticulously guide small suture needles through soft-tissue, the castroviejo needle holder is my instrument of choice when suturing during periodontal plastic procedures.”



Geistlich Mucograft® is measured, cut to size and placed directly onto the defect

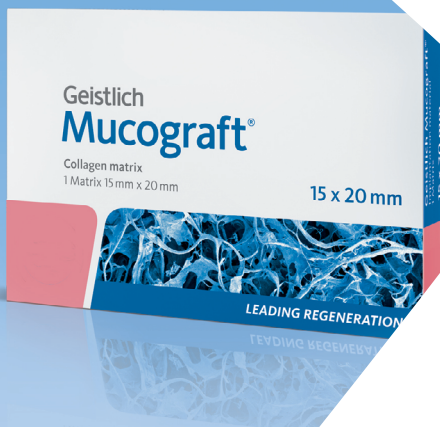

Geistlich Mucograft® in place, adapted to the defect and completely saturated

“Having a thorough knowledge of wound healing can make all of the difference. Every step of the procedure must be planned with the goal of maximizing vascularization of the graft matrix.”

Geistlich
Mucograft®

Specifically designed
for soft-tissue
regeneration



[Click here to view the webinar](#)

Geistlich Pharma North America, Inc.

202 Carnegie Center

Princeton, NJ 08540

Customer Care Toll-free: 855-799-5500

info@geistlich-na.com

www.geistlich-na.com

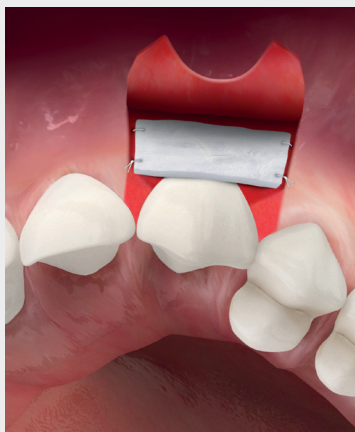ABOUT BIOBRIEF

We know that exposure to new or refined treatment approaches brings innovation to practice. Geistlich Biomaterials is pleased to introduce a periodic opportunity to get up close and personal with creative clinicians from around the world. Focused on peer-to-peer exchange, BIOBRIEF features clinically relevant cases and techniques in specific therapeutic areas – highlighted with valuable insights about materials and instrumentation, as well as KEYS TO SUCCESS.

Geistlich Biomaterials – bringing you *regeneration on time*.

► The Therapeutic Area

Soft-tissue regeneration has gained importance in restoring functionality and esthetics, due to increasing patient demand. Autologous free gingival grafts and connective tissue grafts have been the standard materials used in these procedures, however, harvesting soft-tissue from the palate is painful for the patient and time consuming for the clinician.



CAUTION: Federal law restricts these devices to sale by or on the order of a dentist or physician.

Indications:

Geistlich Mucograft® is indicated for the following uses: Covering of implants placed in immediate or delayed extraction sockets, localized gingival augmentation to increase keratinized tissue (KT) around teeth and implants, alveolar ridge reconstruction for prosthetic treatment, recession defects for root coverage.

Warnings:

As Geistlich Mucograft® is a collagen product allergic reactions may not be totally excluded. Possible complications which may occur with any surgery include swelling at the surgical site, flap sloughing, bleeding dehiscence, hematoma, increased sensitivity and pain, bone loss, redness and local inflammation.

For more information on contraindications, precautions, and directions for use, please refer to the Geistlich Mucograft® Instructions for Use at: www.geistlich-na.com/ifu